

# What to Do After You Cut: Recommendations for Abscess Management in the Emergency Setting



Michael Gottlieb, MD, RDMS\*; Gillian Schmitz, MD; Andrew Grock, MD; Jessica Mason, MD

\*Corresponding Author. E-mail: [michaelgottliebmd@gmail.com](mailto:michaelgottliebmd@gmail.com), Twitter: @MGottliebMD.

0196-0644/\$-see front matter

Copyright © 2017 by the American College of Emergency Physicians.

<https://doi.org/10.1016/j.annemergmed.2017.11.006>



## SEE RELATED ARTICLE, P. 21.

[Ann Emerg Med. 2018;71:31-33.]

**Editor's Note:** *Annals* has partnered with EM:RAP, enabling our readers without subscriptions to EM:RAP to enjoy their commentary on *Annals* publications. This article did not undergo peer review and may not reflect the view and opinions of the editorial board of *Annals of Emergency Medicine*. There are no financial relationships or other consideration between *Annals* and EM:RAP, or its authors.

## ANNALS CASE

Anyone out there seen an abscess recently? We are guessing yes! We know 'em. We love 'em. But most important, everything about their management is cut-and-dried (or cut and squeezed)...right? Well, until a new publication throws doubt on the usual management. Much has changed since the old standard practice of anesthetize, cut, blunt dissect, irrigate, and pack. In this edition of *Annals*, Talan et al<sup>1</sup> published a subgroup analysis on the use of antibiotics for the treatment of skin abscesses, demonstrating an improvement in outcomes regardless of lesion size, a great opportunity to discuss the current data in regard to several aspects of abscess management!

## TO SCAN OR NOT TO SCAN

We all agree that ultrasonography is unlikely to change management for large and easily palpable abscesses. In fact, this has been studied! Marin et al<sup>2</sup> found that ultrasonography did not change the diagnostic accuracy among patients with clinically obvious abscess. However, some cases may be more ambiguous, especially if the abscess is small or evaluation of fluctuation is limited by significant overlying skin changes. One study found that physicians had only fair agreement when clinically assessing for the presence of an abscess among a large sample of children. Among cases that were not clinically evident, ultrasonography significantly increased both the sensitivity and specificity compared with

clinical examination alone.<sup>2</sup> Tayal et al<sup>3</sup> demonstrated that ultrasonography changed management in 73% of patients without clinically obvious abscess!

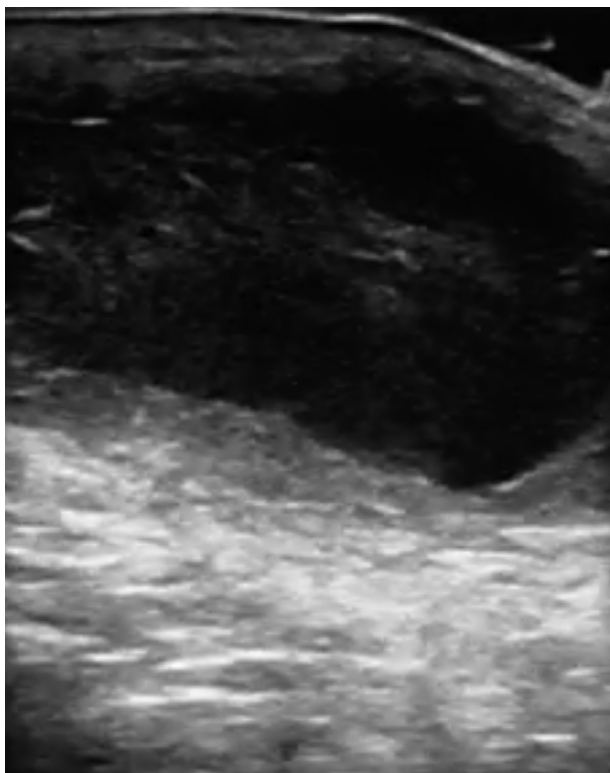
So how good is ultrasonography for the identification of abscess? A recent systematic review and meta-analysis concluded that it is 96% sensitive and 83% specific.<sup>4</sup> Consequently, the American College of Emergency Physicians has included skin and soft tissue ultrasonography as a core application in the updated 2016 clinical ultrasonography guidelines.<sup>5</sup> When evaluating for the presence of an abscess versus cellulitis, one should look for the presence of a clearly demarcated hypoechoic area (fluid collection) with surrounding hyperemia (Figure 1). There should not be evidence of color flow within the abscess, and pressing on it may cause the contents to move in a circle, referred to as the swirl sign. (Patients may have another name for it!)

Okay, so if the diagnosis is not clinically obvious, ultrasonography and then anesthetize, cut, bluntly dissect, irrigate, and pack.

## SO IT'S AN ABSCESS...NOW WHAT?

Although we can all agree that abscesses require drainage, there are a few pearls and pitfalls to improve one's success rates. Incisions along the skin lines (also known as Langer's lines for your next trivia night) will decrease tension on the wound during healing, leading to a lower risk of scarring.<sup>6</sup> Additionally, make sure that the incision is large enough to allow sufficient drainage of the whole abscess.<sup>5</sup> Finally, remember that these procedures really hurt,<sup>7</sup> so make sure to provide adequate local anesthesia, pain medication, or, better yet, a nerve block if possible.<sup>8</sup> And remember, lidocaine requires several minutes to take full effect, so injecting the medication seconds before the procedure won't help much. After injecting might be a great time to see the patient with upper respiratory infection next door to give the lidocaine time to work.

It may seem reasonable to attempt needle drainage, especially when the abscess is easily characterized on



**Figure 1.** Ultrasonography of a fluid collection. Courtesy of Dallas Holladay, DO.

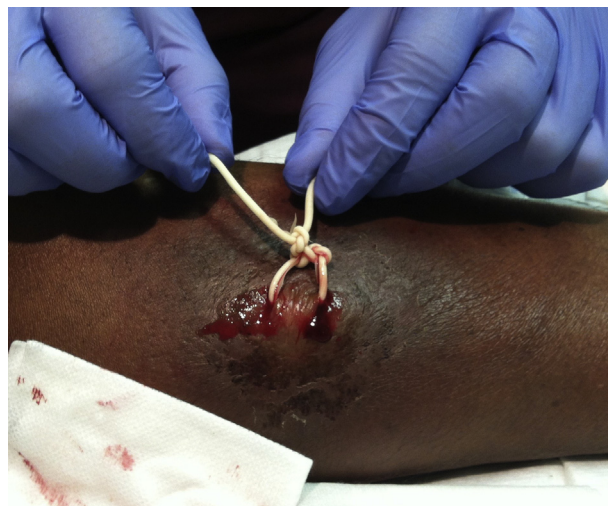ultrasonography. However, one study found that in up to 60% of cases with attempted needle drainage, the provider was unable to adequately drain the abscess despite direct visualization on ultrasonography.<sup>9</sup> More important, patients who were successfully aspirated had significantly worse outcomes than those receiving standard incision and drainage.<sup>9</sup> Therefore, needle drainage is not recommended.

A newer and less invasive procedure, the loop drainage technique, involves making 2 small incisions, bluntly dissecting the loculations, and tying a vessel loop through the openings to facilitate drainage (Figure 2). Don't have a vessel loop? You can use a cut surgical glove instead.<sup>10</sup> Although larger studies are needed, a recent systematic review and meta-analysis found lower failure rates with the loop technique than conventional incision and drainage, as well as decreased scarring and improved patient satisfaction, all tied up with a bow.<sup>11</sup>

OK, new plan: ultrasonography, anesthetize, and consider loop drainage.

### MANAGING THE ABSCESS CAVITY

Although many textbooks recommend irrigation as part of standard incision and drainage, a recent study by Chinnock and Hendey<sup>12</sup> demonstrated no significant difference in outcomes between patients who did and did not



**Figure 2.** Loop drain technique. Courtesy of David Thompson, MD.

receive irrigation. Additionally, this can lead to a longer procedural time, increased pain, higher costs, and microbiologic contamination risk to the provider. Trust us: everyone entering the room after you will be glad you didn't decide to aerosolize the residual pus over the entire room.

Packing is a bit more controversial. One study of 48 adults compared packing with open drainage and found no difference in outcomes.<sup>13</sup> However, the packing group did report higher pain scores and greater use of opioid medications. Another study of 57 pediatric patients also found no statistically significant difference in outcomes.<sup>14</sup> However, both studies were small pilot ones, which were likely underpowered to detect differences in outcomes. For small abscesses (ie, less than 5 cm), it may be reasonable to refrain from placing packing, although conventional teaching remains to pack larger abscesses (or perform loop drainage), pending larger trials.

OK: ultrasonography, anesthetize, cut, and consider loop drainage. For conventional incision and drainage, irrigation is out and packing is controversial.

### BALANCING DRUG AND BUGS

It is classically taught that abscesses are treated with incision and drainage, with antibiotics reserved for cases with significant cellulitis or treatment failure. Several early studies reported that antibiotic treatment did not improve outcome.<sup>15-18</sup> However, because abscesses have high baseline cure rates and all of the studies included relatively small numbers of patients, they were likely underpowered to detect small but clinically significant differences.

In 2016, Talan et al<sup>19</sup> published a large, multicenter trial comparing trimethoprim-sulfamethoxazole (TMP-SMX)

with placebo for uncomplicated skin abscess. Among a sample of 1,247 patients, the TMP-SMX group had a significantly higher cure rate than the placebo group (80.5% versus 73.6%; number needed to treat: 14). Daum et al<sup>20</sup> subsequently reported 786 adults and children with abscesses measuring smaller than 5 cm who were randomized to TMP-SMX, clindamycin, or placebo. Again, the antibiotic treatment groups demonstrated a higher cure rate than the placebo group (83.1% for clindamycin, 81.7% for TMP-SMX, and 68.9% for placebo; number needed to treat: 7). The antibiotic groups were not different, but the clindamycin group had a higher rate of adverse events than either the TMP-SMX or placebo group. However, it is important to consider the consequences of increased antibiotic use, including the potential for resistance and adverse events.

OK, updated plan: ultrasonography, anesthetize, cut, place loop drain, and maybe give antibiotics.

## SUMMARY

Ultrasonography? Helps when there is clinical uncertainty.

Needle aspiration? Not as good as standard incision and drainage.

Incision size? Large enough for adequate drainage or consider the loop technique.

Packing? Jury is still out. Larger trials are needed, although packing is probably not helpful in smaller abscesses.

Irrigation? Nope.

Antibiotics? Complicated... Benefit of a small, clinically significant improvement in cure rates should be weighed against potential risks of antibiotics such as medication adverse effects and increased antibiotic resistance.

---

*Author affiliations:* From the Department of Emergency Medicine, Rush University Medical Center, Chicago, IL (Gottlieb); the Department of Emergency Medicine, Uniformed Services University of the Health Sciences, San Antonio Military Medical Center, Fort Sam Houston, TX (Schmitz); the Department of Emergency Medicine, UCLA–Olive View Medical Center, Sylmar, CA (Grock); and the Department of Emergency Medicine, University of California, San Francisco–Fresno, Fresno, CA (Mason).

---

## REFERENCES

1. Talan DA, Moran GJ, Anusha Krishnadasan A, et al. Subgroup analysis of antibiotic treatment for skin abscesses. *Ann Emerg Med.* 2018;71:21-30.
2. Marin JR, Dean AJ, Bilker WB, et al. Emergency ultrasound-assisted examination of skin and soft tissue infections in the pediatric emergency department. *Acad Emerg Med.* 2013;20:545-553.
3. Tayal VS, Hasan N, Norton HJ, et al. The effect of soft-tissue ultrasound on the management of cellulitis in the emergency department. *Acad Emerg Med.* 2006;13:384-388.
4. Barbic D, Chenkin J, Cho DD, et al. In patients presenting to the emergency department with skin and soft tissue infections what is the diagnostic accuracy of point-of-care ultrasonography for the diagnosis of abscess compared to the current standard of care? a systematic review and meta-analysis. *BMJ Open.* 2017;7:e013688.
5. American College of Emergency Physicians. Ultrasound guidelines: emergency, point-of-care, and clinical ultrasound guidelines in medicine. Available at: [https://www.acep.org/Clinical-Practice-Management/Ultrasound-Guidelines-Emergency-Point-of-care,-and-Clinical-Ultrasound-Guidelines-in-Medicine/?\\_\\_taxonomyid=471332](https://www.acep.org/Clinical-Practice-Management/Ultrasound-Guidelines-Emergency-Point-of-care,-and-Clinical-Ultrasound-Guidelines-in-Medicine/?__taxonomyid=471332). Accessed October 5, 2017.
6. Singer AJ, Talan DA. Management of skin abscesses in the era of methicillin-resistant *Staphylococcus aureus*. *N Engl J Med.* 2014;370:1039-1047.
7. Singer AJ, Richman PB, Kowalska A, et al. Comparison of patient and practitioner assessments of pain from commonly performed emergency department procedures. *Ann Emerg Med.* 1999;33:652-658.
8. Lyons C, Herring AA. Ultrasound-guided axillary nerve block for ED incision and drainage of deltoid abscess. *Am J Emerg Med.* 2017;35:1032.e3-1032.
9. Gaspari RJ, Resop D, Mendoza M, et al. A randomized controlled trial of incision and drainage versus ultrasonographically guided needle aspiration for skin abscesses and the effect of methicillin-resistant *Staphylococcus aureus*. *Ann Emerg Med.* 2011;57:483-491.
10. Thompson DO. Loop drainage of cutaneous abscesses using a modified sterile glove: a promising technique. *J Emerg Med.* 2014;47:188-191.
11. Gottlieb M, Peksa GD. Comparison of the loop technique with incision and drainage for soft tissue abscesses: a systematic review and meta-analysis. *Am J Emerg Med.* 2017; <https://doi.org/10.1016/j.ajem.2017.09.007>.
12. Chinnock B, Hendey GW. Irrigation of cutaneous abscesses does not improve treatment success. *Ann Emerg Med.* 2016;67:379-383.
13. O'Malley GF, Dominici P, Giraldo P, et al. Routine packing of simple cutaneous abscesses is painful and probably unnecessary. *Acad Emerg Med.* 2009;16:470-473.
14. Kessler DO, Krantz A, Mojica M. Randomized trial comparing wound packing to no wound packing following incision and drainage of superficial skin abscesses in the pediatric emergency department. *Pediatr Emerg Care.* 2012;28:514-517.
15. Liera JL, Levy RC. Treatment of cutaneous abscess: a double-blind clinical study. *Ann Emerg Med.* 1985;14:15-19.
16. Lee MC, Rios AM, Aten MF, et al. Management and outcome of children with skin and soft tissue abscesses caused by community-acquired methicillin-resistant *Staphylococcus aureus*. *Pediatr Infect Dis J.* 2004;23:123-127.
17. Duong M, Markwell S, Peter J, et al. Randomized, controlled trial of antibiotics in the management of community-acquired skin abscesses in the pediatric patient. *Ann Emerg Med.* 2010;55:401-407.
18. Schmitz GR, Bruner D, Pitotti R, et al. Randomized controlled trial of trimethoprim-sulfamethoxazole for uncomplicated skin abscesses in patients at risk for community-associated methicillin-resistant *Staphylococcus aureus* infection. *Ann Emerg Med.* 2010;56:283-287.
19. Talan DA, Mower WR, Krishnadasan A, et al. Trimethoprim-sulfamethoxazole versus placebo for uncomplicated skin abscess. *N Engl J Med.* 2016;374:823-832.
20. Daum RS, Miller LG, Immergluck L, et al; DMID 07-0051 Team. A placebo-controlled trial of antibiotics for smaller skin abscesses. *N Engl J Med.* 2017;376:2545-2555.